

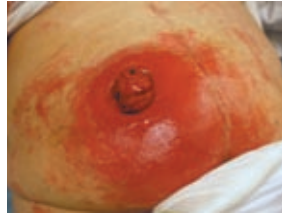A challenging case study on ileostomy skin irritation management

CATHERINE MARTINET, REGISTERED NURSE, ET, UNIVERSITY HOSPITAL OF ROUEN, NORMANDY, FRANCE

Introduction:

Nowadays, the number of ileostomies is increasing due to an increase of temporary ostomies¹. Due to abundant corrosive output², an ileostomy represents a real challenge for an ET nurse.

The knowledge of an ET nurse is prevalent in choosing an appropriate ostomy system, because some leaks may occur due to the use of inadequate systems. Peri-stoma leaks can have serious consequences for the patients;



September 16, 2008 :
Peri-stomal skin irritation.

it can lead to skin irritations and affect social life, self-confidence and health condition.

On September 16, a patient – Mrs. O – was referred to me in emergency with a dramatic skin irritation around her ileostomy.

Diagnosed with Colic Inertia in 1997 (one stool every 2 to 3 month), the patient had undergone multiple intestinal surgeries since 2003, when a total colectomy had been done with an ileo-rectal anatomosis.

Three month after the operation, February 2004, the patient was suffering from severe

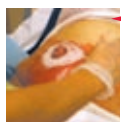diarrhea (15 to 20 motions per day).

Therefore, in July 2005, medical staff decided to divert her small intestine and create an end ileostomy.

Unfortunately, in September 2008 a peristomal edema occurred resulting in several daily appliance leakages. Overwhelmed, Mrs. O stopped using any stoma devices and started applying absorbent bandages instead. The situation went on for about 4 days, until she decided to ask for help.

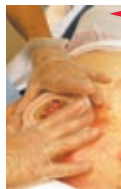Methods & Materials:

The main objective was to keep the system in place more than 2 days to allow the skin to start healing. Thereby the regimen included the following:



September 16, 2008

1- To obtain a dried peri-stomal skin and ensure a better adhesion of the system, Adapt powder was applied over the moist lesion.




September 16, 2008

2- Application of a Conform 2 skin barrier (extended wear). This barrier uses the Flexwear skin barrier and is designed to provide integrity and durability, along with the flexibility. But the main advantage find in this appliance was the floating flange, as it avoids pressure on the abdomen when applying the pouch.

3- Prior to the application of the Conform 2 skin barrier, an Adapt Barrier Ring was moulded on the barrier. Its enhanced resistant properties are used to give a good seal around the stoma and protect the peri-stomal skin from the contact of the corrosive effluents.

4- An Adapt paste was applied directly on the irregular borders of the stoma to enhance the seal around the stoma.

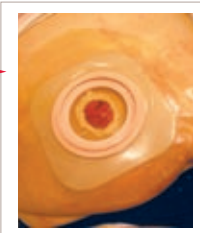


September 16, 2008

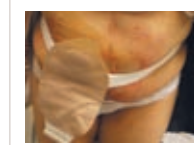5- To obtain a large adherence surface, a hydrocolloid film was applied over the skin barrier.



September 16, 2008



September 16, 2008



September 16, 2008

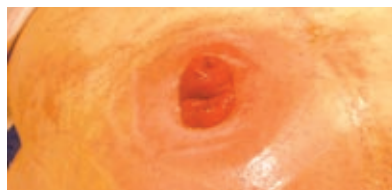6- Finally, an ostomy belt was used to hold the system into place and allow free movement of the patient.

Results & Discussion:

The patient regained self confidence once the problem of the leakages was resolved. She achieved a 3 day wear of the 2P system without any leaks, and just had to change the pouch once a day.

An adapted and secured stoma care system resulted, on September 19, in restoring the damaged skin efficiently.

Once the skin was protected from the effluent, we observed a significant healing of the peri-stomal irritation within 3 days.



September 19, 2008:
The healing of the peri-stomal skin irritation.

To accelerate the healing process, the choice was made not to change her appliance but remain with a 2P system, Conform 2, to achieve a maximum wear time.

The use of accessories, Adapt powder, Adapt paste, Adapt barrier ring, Hydrocolloid film and an ostomy belt, optimized the wear time of the skin barriers.

Also, this report case demonstrates that the quality of care provided for patients with a stoma should be periodically reviewed and formally evaluated, and this is one of the many roles of the stoma care nurse specialist.

Conclusion:

The new challenge of the increasing number of ileostomies gives the stoma care nurse specialist a responsibility in choosing the stoma care device and accessories adapted to the patient skin type. We need to continue meeting patient needs, and satisfaction remains a challenge for us as professionals.

As demonstrated in this case study, stoma care nurses have to be aware that their expertise

is essential for choosing the appropriate appliances which will help patients and avoid potential irritation problems.

After the operation, the stoma care nurses need to be involved in providing the ostomy patient the education and support³.

The discharge process should ensure that the needs and appropriate care of the patient are met once back to their own familiar environment.